

RALEIGH HAND CLINIC

GEORGE S. EDWARDS, JR., M.D.
3410 EXECUTIVE DRIVE
SUITE 105
RALEIGH, NORTH CAROLINA 27609

HAND & UPPER EXTREMITY SURGERY

April 22, 1991

TELEPHONE
(919) 872-3171
(919) 872-5296


John W. Packer, MD
Raleigh Orthopaedic Clinic
P.O. Box 10707
Raleigh, NC 27605

Dear Members:

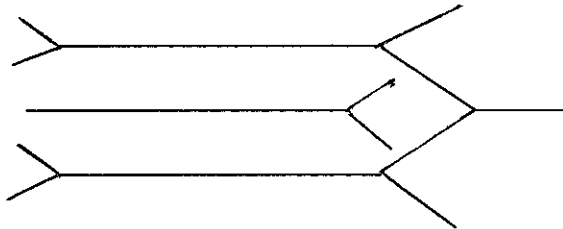
HOW TO DRAW THE BRACHIAL PLEXUS IN 15 SECONDS (OR LESS):

STEP #1

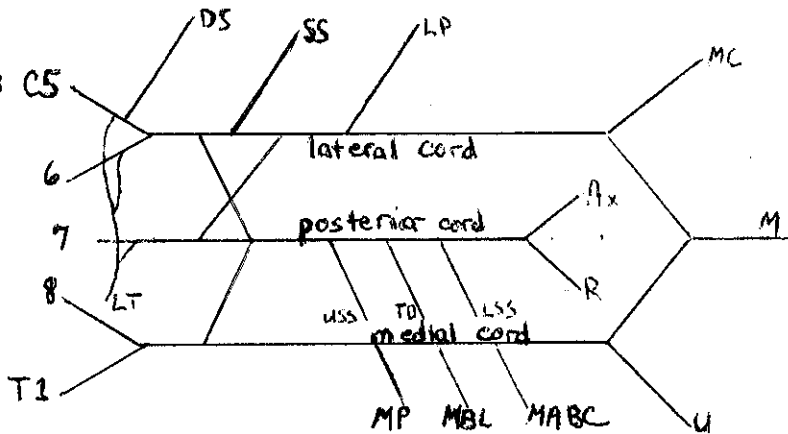
(Left side)



STEP #2



STEP #3



Add 3 branches to each cord plus the long thoracic nerve. This totals 15 branches.

This schematic is useful in analyzing and localizing lesions about the brachial plexus. It is also helpful in teaching anatomy and discussing injuries of the plexus.

My apologies to our Creator and to my mentors (RDL and CAR) for oversimplifying a beautifully complex part of our anatomy.

Respectfully submitted,

George S. Edwards, Jr., MD